



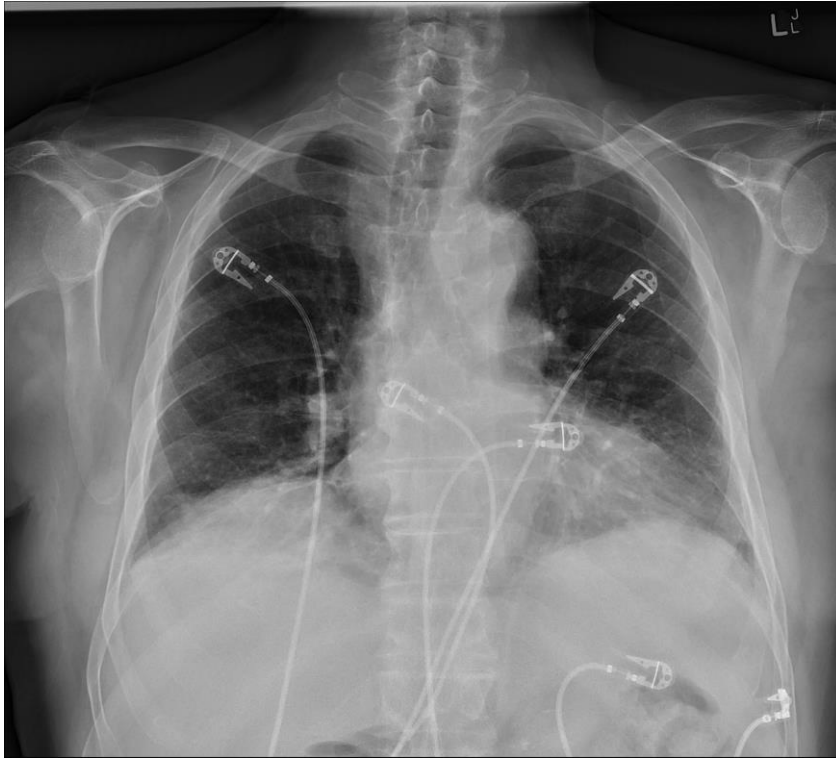
## **Supporting Information**

### **Supplementary figure**

**This appendix was part of the submitted manuscript and has been peer reviewed. It is posted as supplied by the authors.**

Appendix to: Bowden ET, Smith P, Dwyer KM. Pill aspiration: an under-recognised clinical entity. *Med J Aust* 2021; doi: 10.5694/mja2.51337.

**Frontal chest x-ray, showing no focal lung pathology, with symmetrical air entry\***



\* A lateral chest x-ray was also unremarkable.